



OFFICE OF THE MEDICAL EXAMINER

REPORT OF AUTOPSY

DECEDENT: Travis Victor Alexander

CASE: 08-03532

DATE OF EXAMINATION: 06/12/2008

TIME: 0930 Hours

PERSONS PRESENT AT EXAMINATION:

Mesa Police Department:

Detective Esteban Flores #10477

Detective Lisa Barientos #9221

PATHOLOGICAL DIAGNOSES

- I. Sharp force injuries, multiple.
 - A. Stab and incised wounds of head, neck, and torso, multiple, with penetration and hemorrhagic injury of superior vena cava near cardiac base.
 - B. Deeply incised wound of upper neck, with transection of airway and right jugular vein / carotid artery.
 - C. Multiple Incised wounds of hands.
- II. Gunshot wound of head, without exit.
 - A. Gunshot wound of entrance, right forehead, indeterminate range.
 - B. Perforation of inferior skull base, anterior fossa, and facial skeleton.

PATHOLOGIC DIAGNOSES CONTINUED

CAUSE OF DEATH: Sharp force trauma of neck and torso
MANNER: Homicide

07/15/08
Date Signed

KEVIN D. HORN, MD
MEDICAL EXAMINER

TRAVIS VICTOR ALEXANDER

08-03532

PATHOLOGIC DIAGNOSES CONTINUED

- C. No gunshot wound of exit.
 - D. Small caliber deformed projectile recovered from left cheek.
 - E. Wound track trajectory: right to left and downwards.
- III. Blunt force trauma.
- A. Abrasions and contusions of extremities.
- IV. Decomposition, moderate.

REPORTED CIRCUMSTANCES OF DEATH

According to reports, this man was discovered deceased in a state of decomposition in a shower stall in his residence with multiple apparent inflicted injuries. He was pronounced dead at the scene. He had no significant reported past medical history.

EXTERNAL EXAMINATION

The body is received in a zippered body pouch secured by evidence seal #0282712.

CLOTHING AND PERSONAL EFFECTS

None.

EVIDENCE OF MEDICAL INTERVENTION

None.

EVIDENCE OF TRAUMA**SHARP FORCE INJURIES**

There are very numerous incised and stab wounds of the head, neck, torso, and extremities.

Examination of the head reveals the following sharp force injuries:

- Two (2) oblique linear full thickness incised wounds of the right and left posterior scalp, each measuring 2 inches in length
- A 1 ¼ inch oblique stab wound of the lower scalp (over the mastoid process), below the earlobe of the right ear, with an apparent blunt 1/32 inch wide end posteriorly, with penetration into scalp and superficial upper right sternocleidomastoid muscle
- A ¼ inch shallow incised wound of the anteromedial upper left forehead, within the hairline

TRAVIS VICTOR ALEXANDER

08-03532

- Incised and roughly triangular cortical defects of the right and left portions of the skull calvarium, corresponding to the incised defects described above.

Examination of the neck reveals the following sharp force injuries:

- A gaping oblique deep incised wound across the anterior upper neck, 6 x 1 ½ inches with a lower right side (within 2 ½ inches inferior to the right external auditory meatus and 2 inches inferior to the left external auditory meatus), and transection/perforation of the entire upper airway, strap muscles of neck, right jugular vein, and right carotid artery
- A ¼ inch shallow stab wound of the anteromedial upper right neck, with penetration of subcutaneous adipose tissue only
- A 1 ¼ inch oblique stab wound of the lower anteromedial left neck, with penetration of lower medial attachment of left sternocleidomastoid muscle to manubrium
- A 1 inch oblique stab wound of the posterior left neck, with penetration of superficial posterior paraspinal neck muscles.

Examination of the torso reveals the following sharp force injuries:

- A cluster of nine (9) stab wounds of the upper paramidline right and left sides of the back, ranging in size from ¾ to 1 ½ inches, within a 6 x 5 ½ inch area; all wounds display blunt and sharply incised ends; all wounds penetrate soft tissue of back and impact upon ribs and lateral aspects of vertebral bone (transverse laminae and vertebral bodies), without penetration of chest cavity.
- A 1 inch oblique stab wound of the right paramidline neck base / upper back, with penetration into trapezius muscle.
- A 1 inch horizontal stab wound of the upper paramidline left chest, which terminates at the level of the sternum
- A 1 ½ inch oblique stab wound of the paramidline right chest, with penetration / perforation of the costochondral junction near the sternum at the level of the 3rd and 4th right ribs; the wound extends to a maximal depth of approximately 3 ½ inches with penetration of the superior vena cava near the base of the heart, with a small amount of surrounding hemorrhagic in the mediastinal soft tissues and the pericardial sac of the heart; a portion of the costochondral cartilage encompassing the stab wound is excised and retained at the FSC for potential further analysis.
- A deep transverse 2 inch incised wound across the lower right chest, below the nipple, with penetration of the lower portion of the right pectoralis muscle.
- A 1 ¾ inch oblique stab wound of the left upper abdominal quadrant, with a near-tangential subcutaneous adipose tissue wound track (5 ¾ inches long), terminating in adipose tissue of the right lower abdominal quadrant; the abdominal cavity is not penetrated.
- Two (2) very shallow parallel oblique incised wounds of the anterior right shoulder, measuring up to 1 ¾ inch.

The hands were enclosed in paper bags prior to autopsy examination; removal of the bags and examination of the palmar and dorsal aspects of both hands does not reveal

TRAVIS VICTOR ALEXANDER

08-03532

the presence of grossly apparent fine blood spatter or grossly apparent gunpowder fragments. Nails are short and none appear acutely broken, apart from a cut portion of the right thumbnail, as described below. Examination of the hands reveals several sharp force injuries:

- A ¼ inch incised wound of the palmar distal pad of the right thumb, with incision and loss of the lateral portion of the right thumbnail.
- A deep 1 ½ inch incised wound across the left thenar eminence (palmar, with extension onto the dorsal left hand), with deep penetration and partial severing of the musculature and tendons of the thumb base.
- A 1 ¾ inch incised wound of the palmar webbing between the left thumb and index finger, with an adjacent separate ¾ inch linear incised wound
- A 1 inch incised wound across the dorsal surface of the distal inter-phalangeal joint of the left thumb.

GUNSHOT WOUND OF HEAD

There is a 1/8 inch circular gunshot wound of entrance over the anterolateral lower right forehead, above the eyebrow. The wound is located 3 inches inferior to the crown of the head and 1 ½ inches to the right of the midline forehead. There is a 1/8 inch wide equal rim of marginal abrasion surrounding the wound. No soot, gunpowder stippling, or intact gunpowder particles surround the wound.

The wound track perforates the anterior frontal skull near the superior orbital bone and traverses the right anterior fossa, without gross evidence of significant intracranial hemorrhage or apparent cerebral injury (although examination of brain tissue is somewhat limited by the decomposed nature of the remains). The projectile re-enters the facial skeleton near the midline and the wound track terminates in the left cheek.

Palpation and incision of the left cheek reveals the presence of a deformed apparent small caliber projectile, which is located 6 inches inferior to the crown of the head and 4 ½ inches to the left of the anterior facial midline. The projectile is recovered, photographed, and retained as evidence.

There is no gunshot wound of exit.

The wound track trajectory is right to left and downwards.

BLUNT FORCE INJURIES

In addition to the injuries described above, the following blunt force injuries are observed:

- A ¼ inch abrasion of the proximal volar right forearm
- Two (2) blue-purple contusions of the right lower leg and knee
- Two (2) abraded lacerations of the lower lateral left heel and ankle
- A 2 inch blue-purple contusion of the medial malleolus of the left ankle.

TRAVIS VICTOR ALEXANDER

08-03532

EVIDENCE COLLECTION

In addition to the projectile noted above, fingernails and head hair are collected. A modified sexual assault kit is collected (swabs of penis including urethra and swabs/smears of the oral cavity and the anus/rectal vault). No trauma or other abnormalities of the mouth, anus, or genitalia are observed grossly.

SCARS, TATTOOS AND OTHER IDENTIFYING BODY FEATURES

None apparent.

GENERAL EXTERNAL EXAMINATION

The unembalmed body is that of a slightly heavy-set Caucasian male 69 inches in length and weighing 189 pounds. Rigor mortis is absent and livor mortis is red-purple and fixed over the posterior surface of the body. There is evidence of moderate decomposition as indicated by bloating, green discoloration, and multifocal skin slippage with purge exuding from the nose and mouth. The scalp hair is brown. The irides are brown. There are no lesions of the sclerae or conjunctivae. Facial hair is absent. Dentition is natural and in adequate condition. The trachea is in the midline. The thorax is well developed and symmetrical. The abdomen is protuberant with no palpable intra-abdominal masses. The external genitalia are those of normal male. The pubic hair has been previously shaved. The testicles are bilaterally distended within the scrotum. The anus is atraumatic and unremarkable. The extremities are well developed and symmetrical with no significant cyanosis, clubbing, edema or deformity. The posterior aspects of the torso are symmetrical and display extensive trauma as previously described. General appearance is compatible with the reported age of 30.

INTERNAL EXAMINATION

The body is opened by a standard Y-shaped thoracoabdominal incision. All viscera occupy their appropriate anatomic relationships. Subcutaneous adipose tissue ranges up to 3.5 cm in thickness over the abdominal wall. Serous surfaces are smooth and glistening throughout. In addition to the previously described right hemothorax, no other scant accumulations of decomposition fluids in all other body cavities.

CARDIOVASCULAR SYSTEM

The 300-gram heart occupies its usual mediastinal site. The external configuration is unremarkable. The epicardial surfaces are smooth and glistening. All major vessels arise in their appropriate anatomic relationships. The coronary arteries arise normally and are distributed in a right dominant pattern with no significant atherosclerotic stenosis. The myocardium is diffusely soft, green-gray due to decomposition without areas of hemorrhage or gross scarring. No abnormal communications exist between the cardiac chambers. The cardiac valves have thin, pliable leaflets. The valve

TRAVIS VICTOR ALEXANDER

08-03532

circumferences are appropriate to the caliber of the cardiac chambers. The valve cusps and surfaces are free of fusion or vegetations.

The aorta is of normal caliber with all major arterial branches arising in their appropriate anatomic relationship. Elasticity is normal. The intimal surfaces are smooth, without aneurysm formation or dissection. Apart from previously described traumatic injury of the superior vena cava and the carotid artery, no other vascular abnormalities are identified. No venous thrombi are present.

RESPIRATORY SYSTEM

The lungs weigh 340 grams left and 280 grams right. The upper and lower airways are patent and of normal caliber. The pleural surfaces are smooth and glistening. The parenchyma is autolyzed dark red-purple, exuding moderate amounts of blood and intermixed frothy decomposition fluid. There are no areas of induration, consolidation, hemorrhage or gross scarring. The pulmonary vessels are patent and of normal caliber.

DIGESTIVE/HEPATOBIILIARY SYSTEM

The oropharynx is grossly normal and unobstructed. The esophagus is of normal caliber with a smooth, white mucosal lining. The gastroesophageal junction is well defined. The stomach has diffusely flattened mucosal surfaces due to decomposition and the lumen contains approximately 25 mL of brown partially digested food fragments. No areas of ulceration, erosion, or hemorrhage or scarring are present. The small and large intestines are unremarkable. The appendix is present. The lobular tan pancreas is diffusely softened due to decomposition without areas of fat necrosis, gross hemorrhage or space-occupying lesions. The pancreatic ducts are indistinct due to the decomposition process.

The 950-gram liver has a smooth intact capsule, covering variegated brown to black autolyzed parenchyma. No localizing masses, lesions or areas of hemorrhage are evident on external or cut surfaces. The intrahepatic and extrahepatic ducts are patent and of normal caliber. The gallbladder is collapsed and empty. The gallbladder mucosa is autolyzed.

GENITOURINARY SYSTEM

The symmetric kidneys weigh left 150 grams and right 125 grams. They are similar. The capsules strip with ease from the smooth, softened red-brown autolyzed cortical surfaces. The cortices are sharply delineated from the medullary pyramids. The calyces, pelves and ureters are unremarkable. The renal vessels are patent and of normal caliber.

The urinary bladder contains no urine. The mucosal surfaces are flat and pink-tan. The prostate and seminal vesicles are unremarkable.

TRAVIS VICTOR ALEXANDER

08-03532

HEMATOPOIETIC SYSTEM

The 150-gram spleen occupies its usual anatomic site, with an intact, smooth and glistening capsule covering predominantly liquified autolyzed dark purple to brown parenchyma. Regional lymph nodes have their usual distribution and appearance. Rib bone marrow is beefy, red, and unremarkable.

ENDOCRINE SYSTEM

The pituitary, thyroid, and adrenal glands are grossly not remarkable apart from autolysis.

NECK

The cervical spine is structurally intact. The hyoid bone and thyroid cartilage are intact. There is extensive sharp force injury of the upper airway as previously described. Due to decomposition, there are no demonstrable remaining hemorrhages in the strap muscles or soft tissues of the neck. The upper airway is traumatized but patent.

MUSCULOSKELETAL SYSTEM

The bony framework, supporting musculature and soft tissues are unremarkable, except as previously described.

NERVOUS SYSTEM

The scalp is reflected in the usual fashion revealing previously described injuries. The 1525-gram brain is covered by thin, clear, delicate leptomeninges. The dura mater and falx cerebri are intact. There is good preservation of cerebral symmetry with diffuse green-gray softening of parenchyma due to decomposition. Multiple serial sections of autolyzed brain do not reveal the presence of grossly apparent trauma, foreign bodies, or previously existing natural disease. The atlanto-occipital articulation is grossly normal.

EVIDENCE

The following items of evidence are collected and inventoried and released to Conner #16166 of the Mesa Police Department: fingernail clippings and scrapings (right and left hands), blood specimens, paper bags from right and left hands, known head hair, projectile from face, sexual assault kit (penile/urethral swabs, anal swabs and smears, oral swabs and smears), and body bag (including plastic tarp used to wrap body at scene).

A portion of the costochondral junction between the left ribs and the sternum includes a perforating stab wound in this location. This portion of the rib cage and sternal bone is

TRAVIS VICTOR ALEXANDER

08-03532

excised and retained in formalin for potential further analysis. This piece of evidence is retained at the Office of the Medical Examiner.

TOXICOLOGY SPECIMENS

Samples of the following are collected and submitted for toxicological testing: pleural blood, gastric contents, kidneys, spleen, liver, thigh muscle, and brain.

MICROSCOPIC DESCRIPTIONS

Ventricular myocardium (left, right, and septal), lung, liver, kidney: Multiple microscopic sections are reviewed. There is marked postmortem autolysis artefact in all sections, limiting interpretation. The findings are consistent with the gross autopsy impressions and contribute no further significant pathologic diagnoses.

FINAL SUMMARY

Based on the autopsy findings and investigative history, as available to me, it is my opinion that Travis Victor Alexander, a 30-year-old Caucasian male, died as a result of sharp force trauma of the neck and torso.

According to reports, this man was discovered deceased in a state of decomposition in a shower stall in his residence with multiple apparent inflicted injuries. He was pronounced dead at the scene. He had no significant reported past medical history.

Examination revealed the decomposed remains of an adult male with numerous sharp force injuries (incised and stab wounds) of the head, neck, torso, and extremities, with significant injuries of the throat, jugular vein, carotid artery, and a major vein (superior vena cava) in the chest. There was a single penetrating gunshot wound of the head with injuries of the skull and face. Other injuries are detailed in the above report. There were no findings of significant natural disease.

No alcohol (beyond a trace amount associated with decomposition), drugs of abuse, or other significant medications were detected on toxicologic analyses.

The manner of death is homicide.

KDH/gz
D8/12/08
T6/17/08

MARICOPA COUNTY OFFICE OF THE MEDICAL EXAMINER

REPORT OF TOXICOLOGICAL EXAMINATION

Case Number: 08-03532
Decedent: TRAVIS VICTOR ALEXANDER
Date Submitted: 06/12/2008
Report Date: 07/12/2008

Specimens Collected: PLEURAL BLOOD, BLOT/FILTER PAPER, GASTRIC, KIDNEY, SPLEEN, LIVER, THIGH MUSCLE, BRAIN


Medical Examiner: KEVIN D. HORN, MD

RESULTS*:

Pleural Blood: Positive for
Ethyl alcohol 0.01 g%
None detected for methanol, isopropanol, acetone, amphetamine, methamphetamine, phencyclidine, cocaine, benzoylecgonine, methadone, morphine, codeine, benzodiazepines, barbiturates, antihistamines, phenothiazines, tricyclic antidepressants, and fentanyl

Gastric: None detected for amphetamine, methamphetamine, phencyclidine, cocaine, methadone, codeine, antihistamines, phenothiazines, and tricyclic antidepressants

*If results are not listed for any specimen(s), that/those specimen(s) is/are deemed to be on "HOLD"


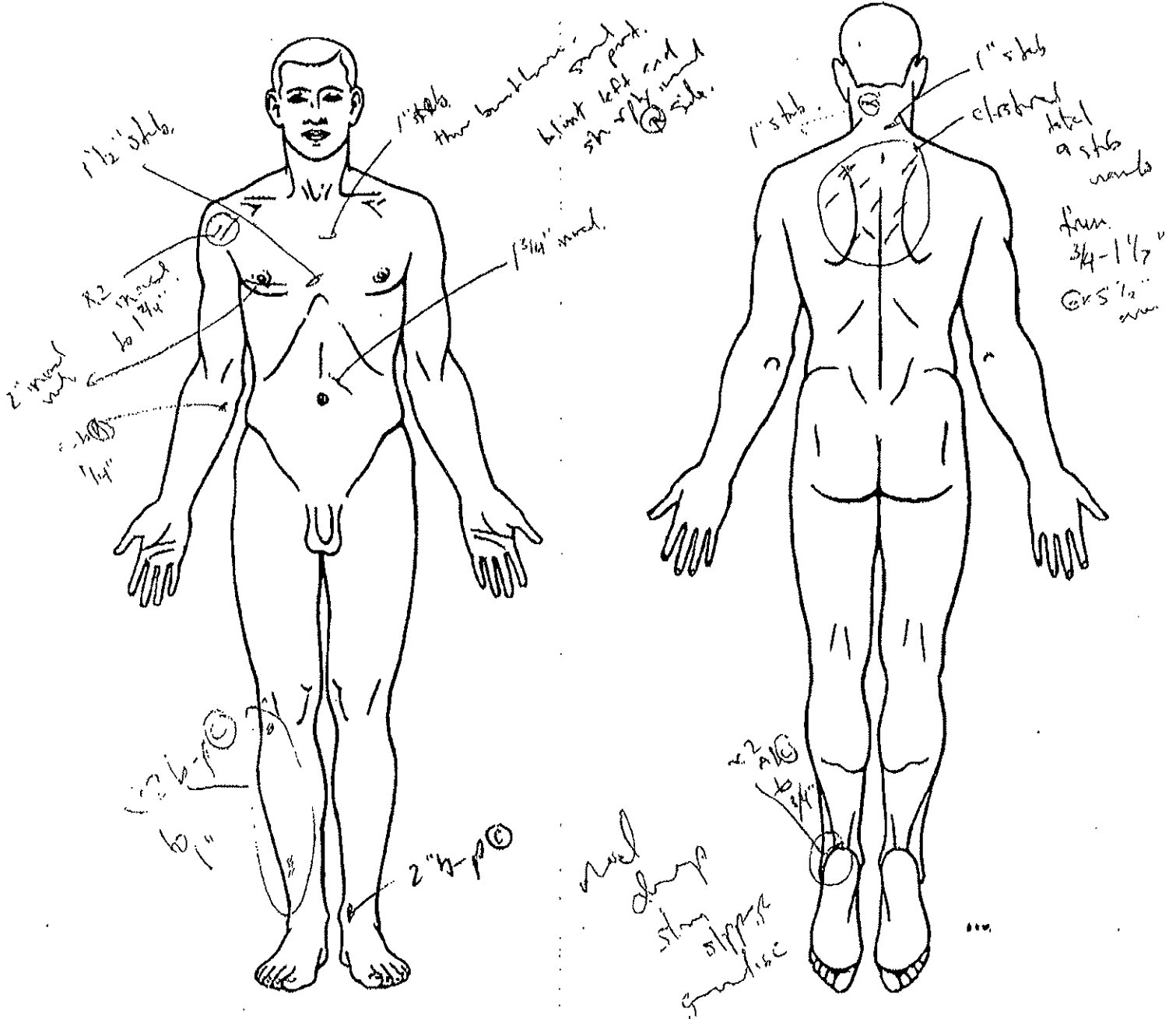

Norman A. Wade
Laboratory Director

Jurisdictional Agency: MESA PD
By:gz; Tox. 1/2000; DAWN:

KDH
07/15/08

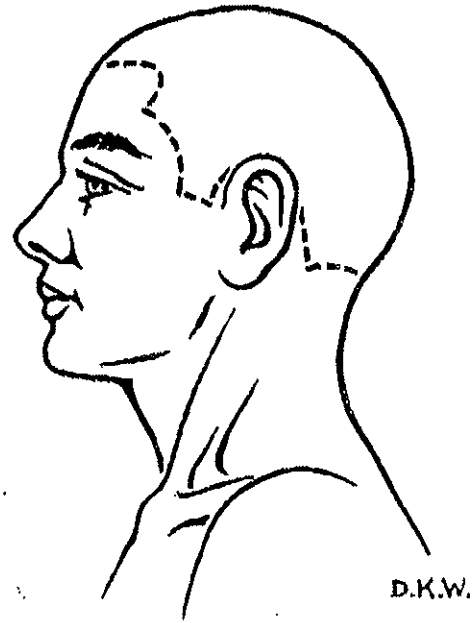
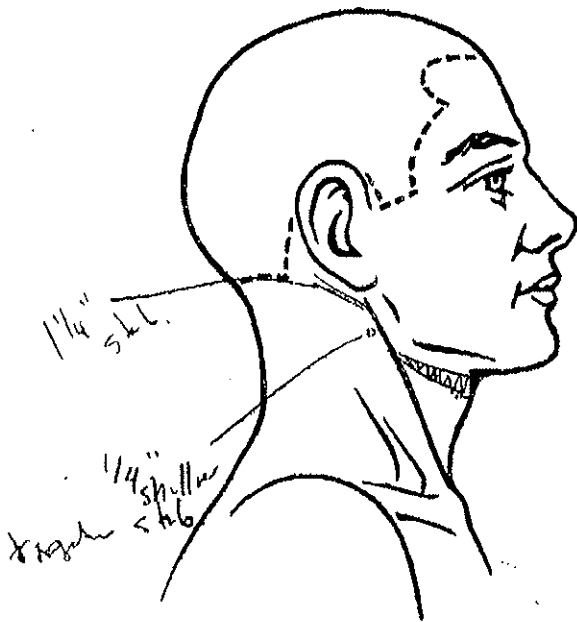
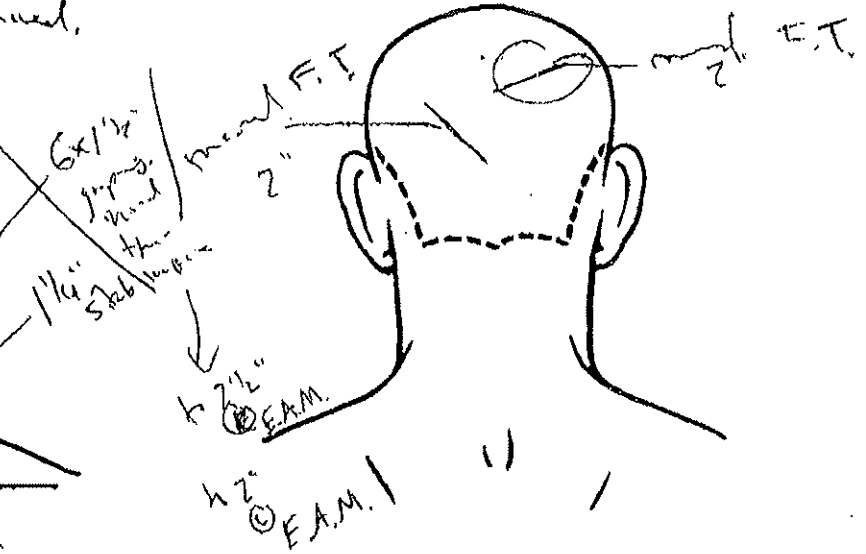
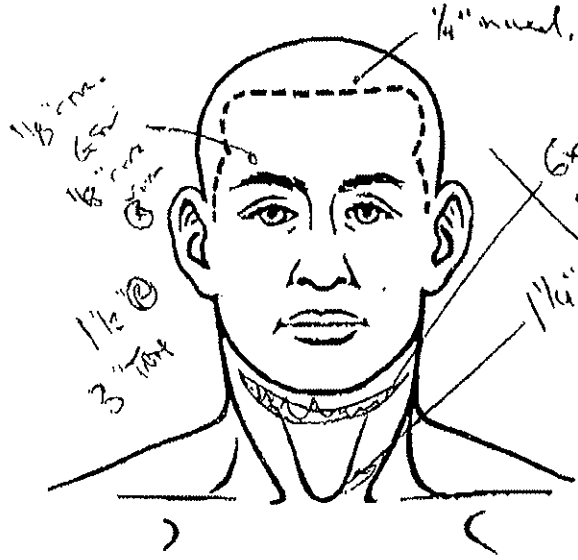
Maricopa County Office of the Medical Examiner
Forensic Science Center

⊕ bags



Hair Color	br	Eye Color	br
Teeth	Wt wt	Beard	(X)(N)
Weight	189	Mustache	(Y)(N)
Height	69	Clothing	⊙
Rigor	⊙		
Livor	(-)(+) to part.	Seal No.	0282712

Maricopa County Forensic Science Center



FOR OFFICIAL USE ONLY
 MARICOPA COUNTY FORENSIC SCIENCE CENTER
 1000 WEST PUEBLO AVENUE
 MESA, AZ 85201

Maricopa County Office of the Medical Examiner
Forensic Science Center

